

Thirteen-year follow-up of a cross-arch implant-supported fixed restoration in a patient with generalized aggressive periodontitis and parafunctional habits

Abstract

Background

As implant treatment becomes part of mainstream dental therapy, dental offices should implement protocols for individualized, systematic and continuous supportive care of the periimplant tissue. This article describes the 13-year management of a patient with generalized aggressive periodontitis and bruxism treated using Brånemark TiUnite implants with machined collars.

Materials and methods

In the upper jaw, a cross-arch implant-supported fixed restoration was delivered. In the lower jaw, an implant-supported fixed partial prosthesis was provided, retaining some natural dentition, which increased the risk of a periodontal reservoir. Treatment included multiple extractions and submerged implants. Implant survival rate, patient satisfaction, marginal bone maintenance and soft-tissue condition at the modified titanium surfaces of the dental implants were evaluated up to 13 years of function.

Results

Two adjacent implants were lost 3 years after loading owing to periimplantitis and these were not replaced. One implant had bone loss after recementation and retained cement that subsequently responded to intervention with bone recovery. Furthermore, the maxillary prosthesis was remade once after 3 years of function, owing to porcelain breakage in the esthetic zone.

Conclusion

This clinical case may provide information about benefits of a long-term patient history follow-up, with emphasis on periodontal and occlusal risks. A comprehensive diagnosis, multifactorial approach, good clinician-patient relationship and vigilant maintenance of oral hygiene were needed in order to ensure an optimal treatment and a successful long-term result.

Keywords

Dental implants, long-term follow-up, periodontally compromised patients, periodontitis, supportive periodontal therapy.

David French^a & Erta Xhanari^b

^a Private practice, Calgary, Alberta, Canada

^b Aldent University, Tirana, Albania

Corresponding author:

Dr. David French

3625 Shaganappi Trail Nw Suite 212
Calgary, AB T3A 0E2
Canada

T +1 403 247 8657
drfrench@shaw.ca

How to cite this article:

French D, Xhanari E. Thirteen-year follow-up of a cross-arch implant-supported fixed restoration in a patient with generalized aggressive periodontitis and parafunctional habits. *J Oral Science Rehabilitation*. 2017 Sep;3(3):48–55.

Introduction

Endosseous dental implants have been widely used to aid the support of restorations replacing missing teeth. This has been widely reported in the literature dating back to the early 1960s.^{1,2} Implants have added predictable treatment options for patients, clinicians and dental technicians.^{3,4} Nevertheless, technical and biological complications may occur either at an early stage, owing to failed integration during healing, or later, regarded as loss of integration and stability after healing and during functional loading.⁵ Smoking, low bone density, irradiation, infection, relative overload, previous periodontitis and parafunctional habits, such as bruxism, are some of the described risk factors that may lead to implant failure.^{5,6} In the case of parafunctional habits, in a systematic review, it was noted that treated patients with periodontitis may experience more implant loss and biological complications compared with nonperiodontitis patients with implants.⁴ During the first year of function, a certain amount of physiological marginal bone loss is often observed around a dental implant, and this probably reflects remodeling/adaptation after surgery⁷ and during loading;⁸ thereafter, minimal further bone loss has been annually observed.^{6,9} As a consequence, the prerequisites for implant success are marginal bone loss of up to 1.0 mm within the first year of implant loading and successive annual mean marginal bone loss of 0.2 mm during the follow-up period.^{9,10} Continuous bone loss with clinical signs of infection, such as bleeding and suppuration, is referred to as periimplantitis, irrespective of the sequence of events.¹¹ Depending on the definition used, the prevalence of progressive bone loss/periimplantitis in long-term studies has been reported to range from 7.7 to 39.7%.¹² Periodontally healthy patients and patients with chronic adult periodontitis show no difference in periimplant variables and implant survival rate, but patients with generalized aggressive periodontitis have greater periimplant pathology, more marginal bone loss and a lower implant survival rate.¹³ Furthermore, it is of interest to note that the impact of a history of periodontitis on early implant loss was found to be negligible in patients that have been treated with supportive periodontal therapy.¹⁴ However, in the long term, periimplantitis was detected more than twice as frequently in periodontally compromised than in periodontally healthy subjects.^{13,15}

Furthermore, based on clinical experience, it has been noted that bruxers are a high-risk category regarding successful implant outcomes and this has been reported in the literature.¹⁵ Studies have reported more frequent technical complications, including implant loss, in bruxers.¹⁶

This case report describes the 13-year management of a patient with generalized aggressive periodontitis and bruxism treated using Brånemark TiUnite implants (Nobel Biocare, Yorba Linda, Calif., U.S.) with machined collars. In the upper jaw, a cross-arch implant-supported fixed restoration was delivered. In the lower jaw, an implant-supported fixed partial prosthesis was provided, retaining some natural dentition, which increased the risk of a periodontal reservoir.

Case report

A 57-year-old woman with a history of generalized aggressive periodontitis presented to our clinic for a periodontal consult and treatment in 2003. Despite an overall full-mouth root planing, multiple surgeries and antibiotics, the patient continued to exhibit progressive bone loss. Two years after the initial consult, a comprehensive clinical, radiographic and study cast evaluation found that the remaining dentition showed recurrent abscesses with progressive bone loss due to chronic periodontal disease (**Fig. 1**). Furthermore, the case was complicated by pathological tooth mobility, furcation involvement at the maxillary molars, occlusal instability and parafunctional habits, including bruxism.

Various treatment options were discussed with the patient, including maxillary and mandibular conventional removable complete dentures, as well as implant-supported overdenture or implant-supported fixed restorations. The patient's chief desire was to replace her existing teeth with implant-supported fixed restorations without conventional removable complete dentures or removable prostheses. After detailed consultation, the extraction of all of the remaining maxillary dentition and its replacement with dental implants were suggested. The patient understood and agreed to the treatment plan and was informed about the higher risk of implant failure owing to her periodontal disease and bruxism, especially if some natural teeth were retained. The standard outcome in these cases is up to 98.05% at the 10-year follow-up,¹⁷ but owing to the pre-existing periodontal disease and bruxism, the success rate was expected to be

Fig. 1
Pretreatment photograph:
frontal view.

Fig. 2
Implants placed in the upper
jaw after the second-stage
surgery.

Fig. 3
Implants placed in the lower
jaw after the second-stage
surgery.

decreased to 90% at the 10-year follow-up.^{12, 13} The outcome would be dependent on the patient's daily routine, home care and professional recall visits. The patient decided to proceed with rehabilitation of the upper arch with a fixed complete denture, being aware of the associated cost, advantages and disadvantages. Comprehensive clinical, radiographic and study cast evaluation found that the previously placed implant in the maxilla (TiUnite machined collar Brånemark System MkIII, Nobel Biocare), inserted in the left central area to restore a tooth lost to an endodontic fracture complication in 1999, could be maintained for planned rehabilitation.

Three months after removal of the teeth and residual ridge healing, 7 Biocare replace implants (Nobel Biocare) were placed in additional sites across the maxillary arch. Simultaneously, extractions were performed of the mobile teeth in the right mandibular posterior site. Four months after extraction, 3 Biocare replace implants were placed to replace the extracted teeth. Bone grafting was not required for all procedures. All of the placed implants achieved stability at placement and were fully osseointegrated, evidenced by radiography and clinical torque testing to 35 N cm, performed 3 months after insertion, during healing abutment connections (**Figs. 2 & 3**). Finally, the case was referred to a prosthodontist for full-arch upper fixed-removable and partial-arch fixed tooth form prostheses. All efforts were made to retain some access for a proxy brush under the prosthesis to reduce the periimplantitis risk. The maxillary and mandibular prostheses were seated with custom titanium abutments using a temporary cement (Improv Temporary Implant Cement, Salvin Dental Specialities, Charlotte, N.C., U.S.). The patient had regular visits for periodontal control and maintenance in a well-organized scheme with appointments over the years.

The maxillary prosthesis was remade once after 3 years of function, owing to porcelain breakage in the esthetic zone. However, after the remake, the patient improved compliance regarding use of the bruxism appliance and the prosthesis remained intact and functional for over 11 years.

Nevertheless, there was progressive bone loss at a Class 3 furcation site of the mandibular first molar (**Fig. 4**) that responded to root resection therapy in 2003 and remained stable thereafter (**Fig. 5**). The overall reduced periodontal disease activity may in part be due to

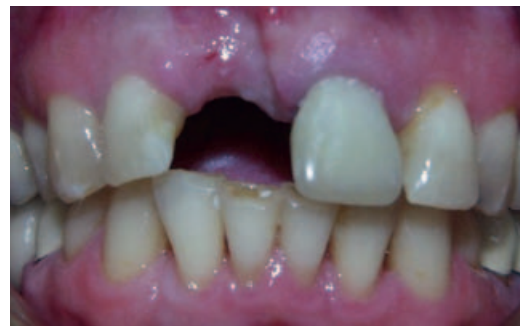

Fig. 1

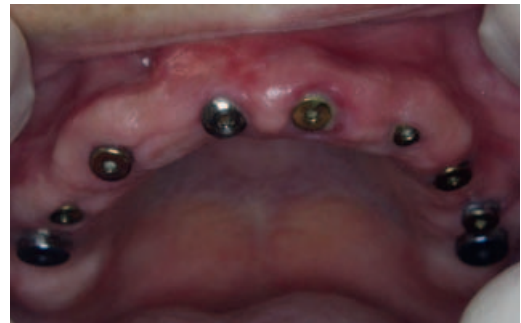

Fig. 2

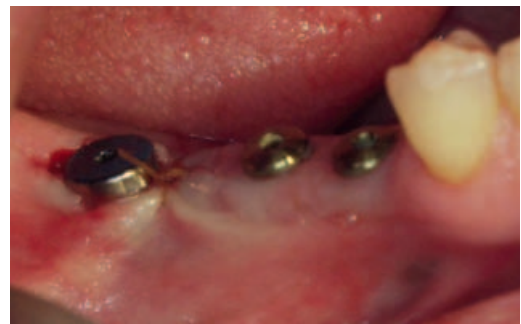

Fig. 3

the extraction of most of the involved teeth and in part to long-term therapy with a daily dose of 100 mg of minocycline for acne, begun by the patient in 2004, then switched in 2008 to 100 mg of doxycycline, cut into quarters and taken daily. Despite her progressive periodontal history, the bone loss at the implants showed the typical pattern of about 0.5 mm of bone loss beyond the machined collar and at most sites there was no sign of periimplantitis related to marginal bone loss. However, there were two sites in the left maxillary molar area where periimplant bone loss had developed. The implants placed at this position were both lost after 3 years of loading, primarily related to implant proximity between them, limiting proper oral hygiene access (**Figs. 6 & 7**). These implants were not replaced and the prosthesis was retained with a distal cantilever pontic at the first molar area off the most distal implant site at the second premolar area in the full-arch prosthesis. Acute suppuration and about 2 mm

Fig. 4

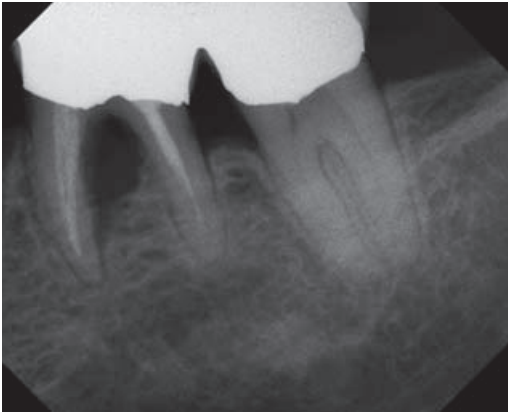


Fig. 5

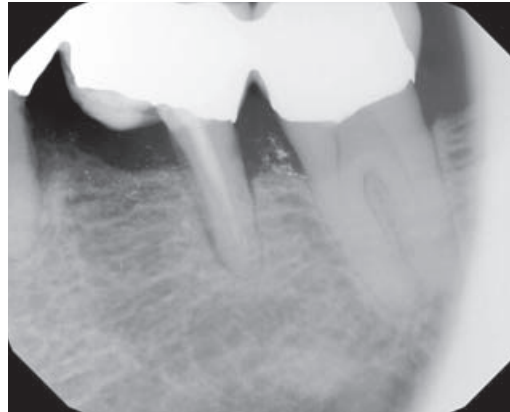


Fig. 4

Teeth affected by periodontitis in the left lower jaw.

Fig. 5

Root resection therapy performed on the left mandibular first molar.

Fig. 6

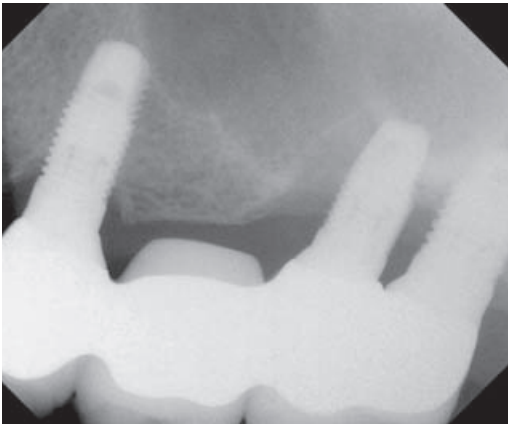


Fig. 7

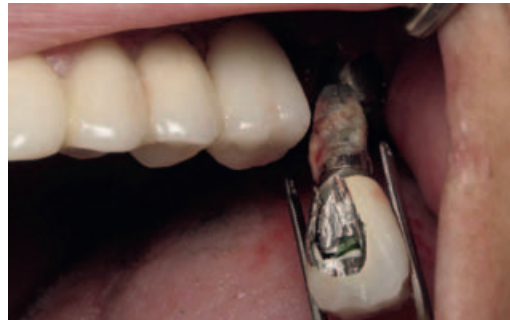

Fig. 6

The 2 implants in the left upper jaw affected by periimplantitis.

Fig. 7

Removal of the implants.

Fig. 8

Periimplant bone loss at the left mandibular second molar.

Fig. 9

The left mandibular second molar site shown fully recovered.

Fig. 8

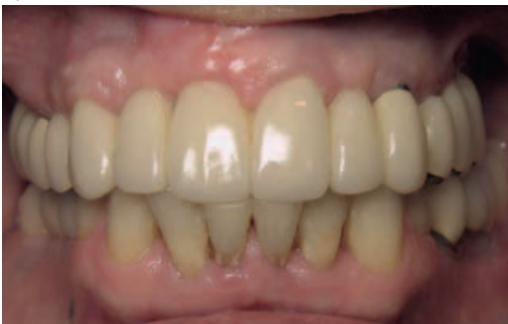
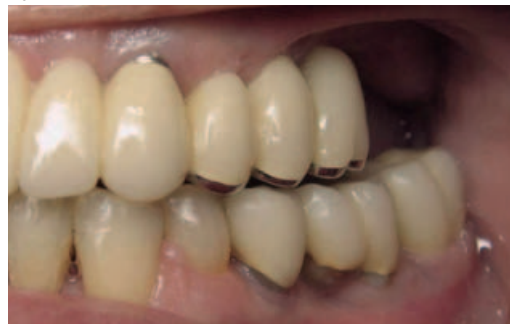
Fig. 9



of periimplant bone loss were also observed at the 6-year follow-up at the right mandibular second molar implant (**Fig. 8**), related to retained cement that was noted about 6 months after a recementation of the splinted crowns. A flap was raised at the right mandibular molar area, then the exposed TiUnite surface was decontaminated with citric acid and hard-tissue defect walls and soft-tissue excess were reduced as part of flap closure. At the 7-year follow-up examination, subgingival irrigation with minocycline hydrochloride microspheres (Arestin, OraPharma, Valeant Pharmaceuticals International, Laval, Quebec, Canada) was performed. At the year 8 visit, the right mandibular

second molar site had fully recovered bone reformation (**Fig. 9**). Although the patient had active periodontal disease activity, good clinical (**Figs. 10 & 11**) and radiographic (**Fig. 12**) outcomes were illustrated at the 8-year follow-up visit, owing to the impact of supportive periodontal therapy.

At the year 13 visit, the second molar still remained stable in response to intervention, with a full recovery of historic bone loss that was once about 2 mm beyond the machined collar. Good clinical (**Figs. 13 & 14**) and radiographic (**Figs. 15a & b**) outcomes were recorded at the 13-year follow-up visit, owing to good oral hygiene maintenance and regular recall.

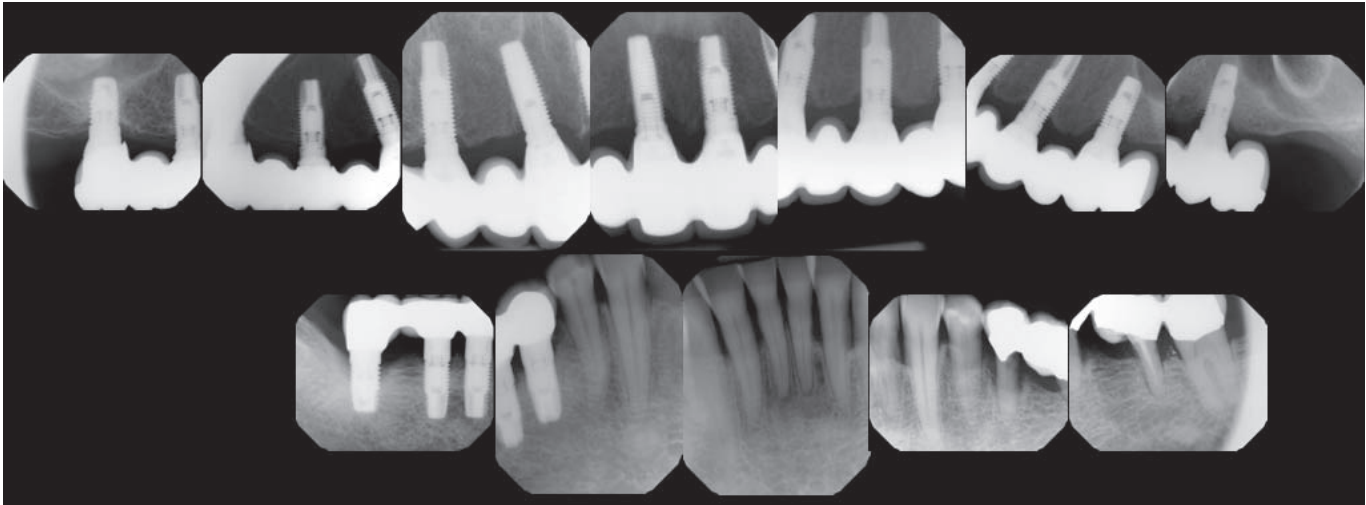


Fig. 10

Fig. 10
New prosthesis and follow-up after 8 years: right side view.

Fig. 11
New prosthesis and follow-up after 8 years: frontal view.

Fig. 12
New prosthesis and follow-up after 8 years: radiographs.

Fig. 13
Follow-up after 13 years: frontal view.

Fig. 14
Follow-up after 13 years: right side view.

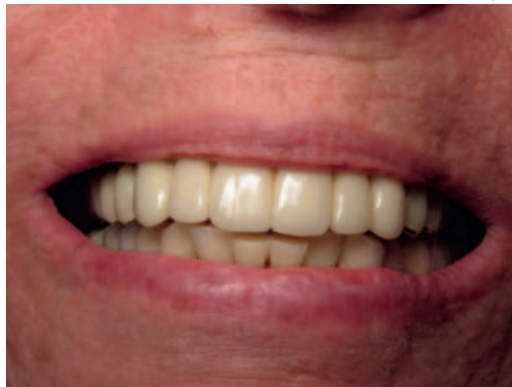

Fig. 11

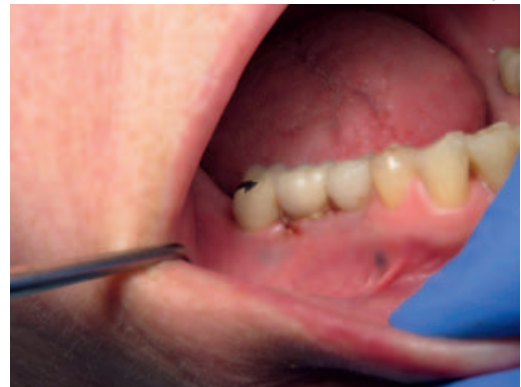

Fig. 12

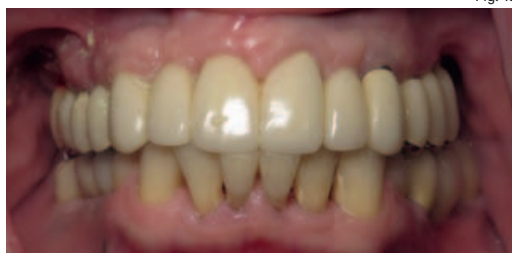

Fig. 13

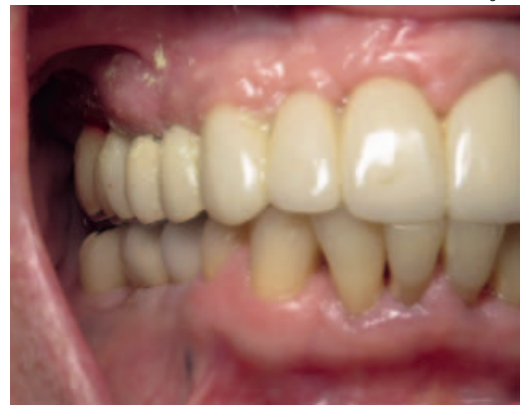

Fig. 14

Discussion

Little is known about the long-term outcome of implants with oxidized surfaces, especially in periodontitis-susceptible patients. The management of this case presented a challenge to the treating clinician, as the patient presented with generalized aggressive periodontitis complicated by bruxism. Supportive periodontal control and maintenance following a predesigned subject-tooth, implant site risk assessment

method is of key importance for long-term success after periodontal surgery.^{18, 19} The two implant losses at the 3-year time point were in accordance with the literature finding that patients with a history of generalized aggressive periodontitis are more clearly prone to late failure rates, even when minimally rough implants are used when periodontal therapy is followed.²⁰ Complicating factors such as implant proximity and retained cement may have been the initiating factors.

Fig. 15a

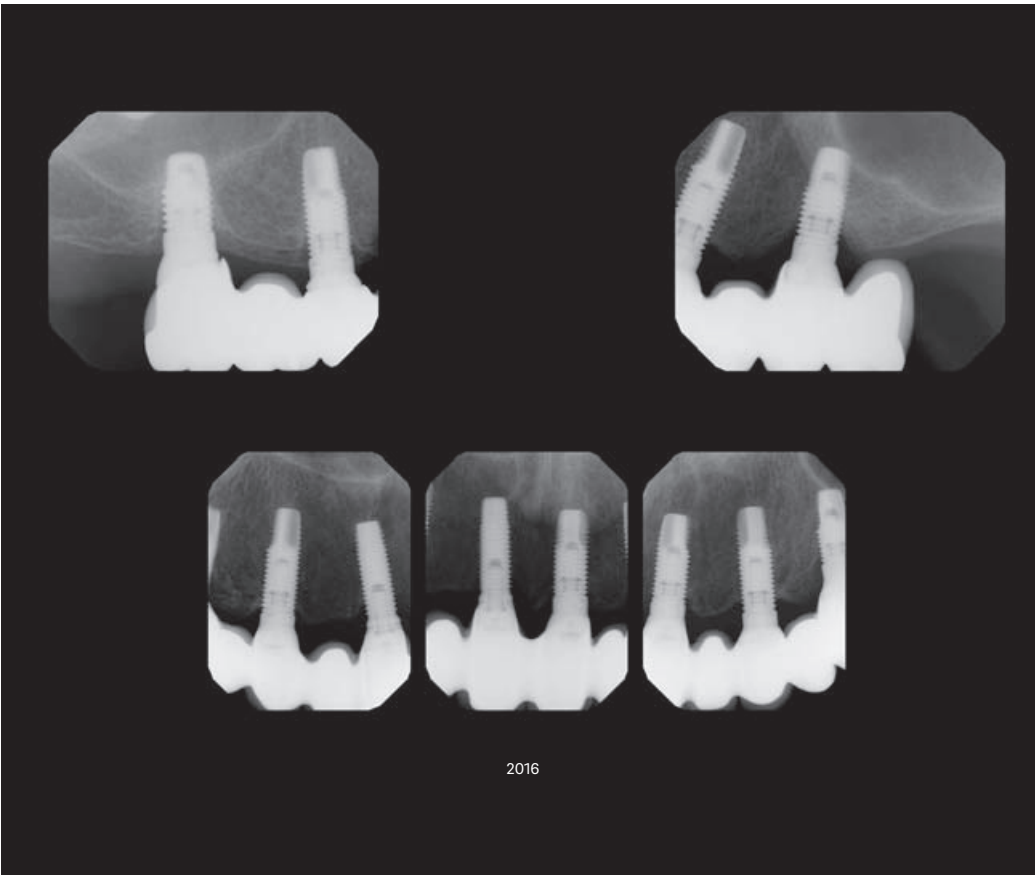

Fig. 15a

Radiographic follow-up of the maxillary molars up to 13 years.

Fig. 15b

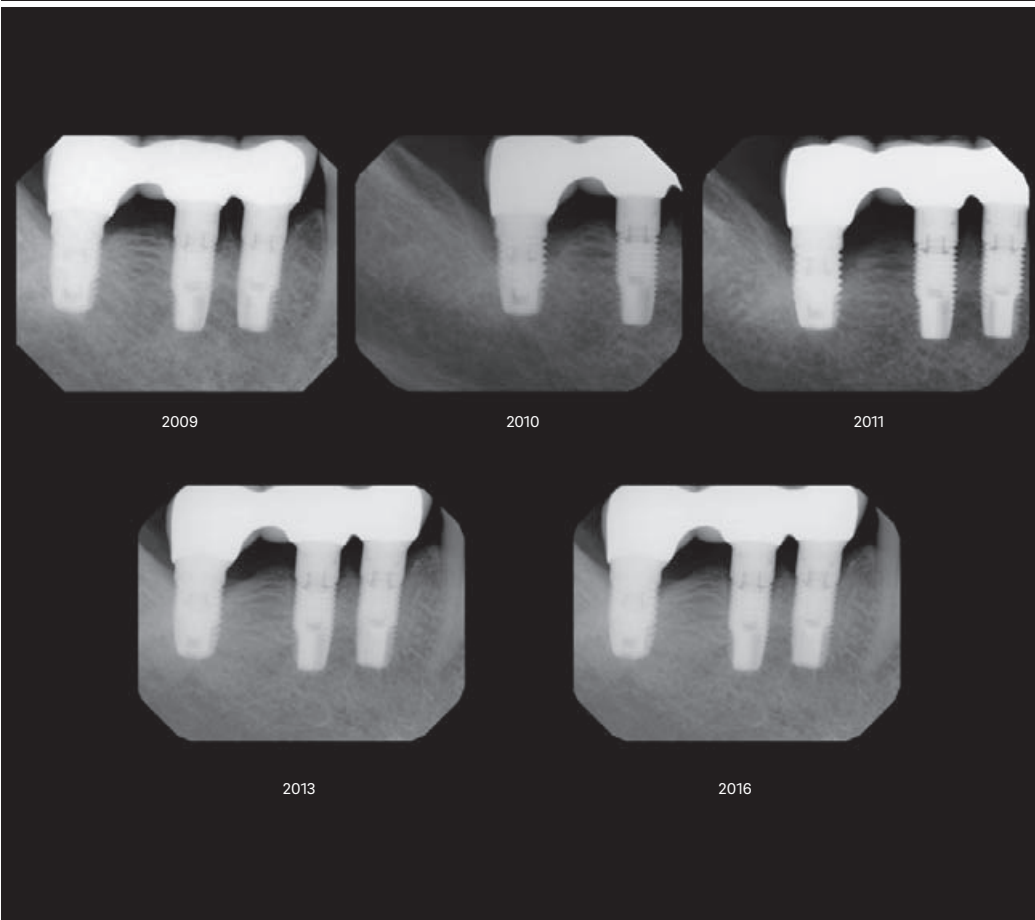


Fig. 15b

Radiographic follow-up of the right mandibular second molar from the start of the periimplantitis up to the 13th year of follow-up.

Varying degrees of marginal bone loss are normally seen around dental implants, regardless of all the efforts to eliminate it.²¹ Maintenance and improvement of periimplant bone, as well as the establishment and maintenance of a soft-tissue barrier around the implant abutment, are prerequisites for long-term esthetic and functional success of an implant-supported restoration.⁵ However, during clinical function, some implants may show extensive and sometimes continuous bone loss, whose primary cause is not well understood. Previous authors have proposed several factors that may increase marginal bone loss around dental implants, including surgical trauma, biological width establishment, lack of passive fit of the superstructure, implant–abutment microgap and occlusal overload.^{21,22} Continuous bone loss with clinical signs of infection, such as bleeding and suppuration, is referred to as periimplantitis, irrespective of the sequence of events.¹² Depending on the definition, the prevalence of continuous bone loss in long-term studies has been reported to range from 7.7 to 39.7%;¹² however, some authors have regarded this as unrealistically high.¹⁰ These figures are mainly based on implants with a machined and relatively smooth surface. Today, most implants have some type of surface treatment to promote a stronger bone tissue response, such as blasting, etching, anodic oxidation and combinations of techniques.^{23, 24} The moderately rough, highly crystalline, and phosphate-enriched titanium oxide surface of the TiUnite implants features an increased titanium dioxide layer, a moderately rough microstructure that enlarges the osseointegrable surface area, and it has been reported to enhance the adhesion of human osteoblastlike MG-63 cells to titanium without significantly affecting the pattern of gene expression.²³ Concerns have been raised that bone loss and subsequent exposure of a rough implant surface may facilitate establishment of a periimplant infection.²⁴ Though the numbers of longer-term follow-up are small, positive clinical and radiographic performance of implants with a porous anodized surface has been reported.^{18, 24} This contradicts a short-term animal study that stated that the porous anodized surface of TiUnite is more susceptible to progressive periimplant loss once established.²⁵

In the presented case, the patient's chief desire was to have her hopeless teeth replaced with implant-supported fixed restorations, keeping the remaining teeth. The patient

understood and agreed to the treatment plan and was informed about the higher risk of implant failure owing to her periodontal disease. The outcomes of this case depended on patient compliance with the periodontal program. Follow-up and intervention, when indicated, are important in a case with a history of periodontal disease. In particular, the good outcome at site 47 demonstrates the benefit of flap intervention to remove retained cement and, potentially, the added benefit of subgingival antimicrobial delivery to address periimplantitis and recover lost radiographic bone despite prior infection and bone loss. This would suggest that a contaminated microrough surface does not always lead to progressive bone loss if there is suitable intervention. Also in this case, the usage of the bruxism appliance was critical to reduce potential biological and technical complications. According to a recent systematic review, bruxism is unlikely to be a risk factor for biological complications around dental implants, but it is more likely to be a risk factor for technical complications.¹⁶ The caution that is urged when using implants to support dental prostheses in bruxers is due to the common fear that bruxism can cause overloading and may affect osseointegration and/or compromise the integrity of technical components and veneering materials. Keeping this in mind, care must be exercised in periodic control of occlusal design and presence of nonaxial loads on implant-supported restorations, and adequate levels of oral hygiene must be maintained in the long term in order to avoid increasing the risk of periimplant disease.

Conclusion

Implant treatment in patients exhibiting ongoing active periodontal disease and bruxism is not contraindicated provided that adequate infection control and an individualized maintenance program are assured. The results of this case illustrated good clinical and radiographic outcomes with long-term prosthetic stability. Confounding factors, such as the minimally rough surface of the implant, did not seem to cause bone loss.

Competing interests

The authors declare that they have no competing interests.

References

1. Schröder F. Bone and cartilage reconstructions after use of implants. → *Trans Int Conf Oral Surg.* 1967;398–403.
2. Cobb Jr. Subperiosteal vitallium implants in dogs. → *Oral Surg Oral Med Oral Pathol.* 1960 Oct;13:1153–62.
3. Brånemark PI, Hansson BO, Adell R, Breine U, Lindström J, Hallén O, Ohman A. Osseointegrated implants in the treatment of the edentulous jaw. Experience from a 10-year period. → *Scand J Plast Reconstr Surg Suppl.* 1977;16:1–132.
4. Adell R, Lekholm U, Rockler B, Brånemark PI. A 15-year study of osseointegrated implants in the treatment of the edentulous jaw. → *Int J Oral Surg.* 1981 Dec;10(6):387–416.
5. Sennerby L, Roos J. Surgical determinants of clinical success of osseointegrated oral implants: a review of the literature. → *Int J Prosthodont.* 1998 Sep-Oct;11(5):408–20.
6. Albrektsson T, Zarb GA, Worthington P, Eriksson AR. The long-term efficacy of currently used dental implants: a review and proposed criteria of success. → *Int J Oral Maxillofac Implants.* 1986 Summer;1(1):11–25.
7. Pozzi A, Agliardi E, Tallarico M, Barlattani A. Clinical and radiological outcomes of two implants with different prosthetic interfaces and neck configurations: randomized, controlled, split-mouth clinical trial. → *Clin Implant Dent Relat Res.* 2014 Feb;16(1):96–106.
8. Brånemark PI, Svensson B, van Steenberghe D. Ten-year survival rates of fixed prostheses on four or six implants ad modum Brånemark in full edentulism. → *Clin Oral Implants Res.* 1995 Dec;6(4):227–31.
9. Jemt T, Albrektsson T. Do long-term followed-up Brånemark implants commonly show evidence of pathological bone breakdown? A review based on recently published data. → *Periodontol 2000.* 2008;47:133–42.
10. Oh TJ, Yoon J, Misch CE, Wang HL. The causes of early implant bone loss: myth or science? → *J Periodontol.* 2002 Mar;73(3):322–33.
11. Albrektsson T, Isidor F. Consensus report of Session IV. → In: Lang NP, Karring T, editors. *Proceedings of the first European Workshop on Periodontology.* London: Quintessence. 1994. p. 365–9.
12. Mombelli A, Müller N, Cionca N. The epidemiology of peri-implantitis. → *Clin Oral Implants Res.* 2012 Oct;23 Suppl 6:67–76.
13. Klinge B, Meyle J; Working Group 2. Peri-implant tissue destruction. The Third EAO Consensus Conference 2012. → *Clin Oral Implants Res.* 2012 Oct;23 Suppl 6:108–10.
14. Quirynen M, Abarca M, Van Assche N, Nevins M, van Steenberghe D. Impact of supportive periodontal therapy and implant surface roughness on implant outcome in patients with a history of periodontitis. → *J Clin Periodontol.* 2007 Sep;34(9):805–15.
15. Roccuzzo M, Bonino F, Aglietta M, Dalmasso P. Ten-year results of a three arms prospective cohort study on implants in periodontally compromised patients. Part 2: clinical results. → *Clin Oral Implants Res.* 2012 Apr;23(4):389–95.
16. Manfredini D, Poggio CE, Lobbezoo F. Is bruxism a risk factor for dental implants? A systematic review of the literature. → *Clin Implant Dent Relat Res.* 2014 Jun;16(3):460–9.
17. French D, Larjava H, Ofec R. Retrospective cohort study of 4591 Straumann implants in private practice setting, with up to 10-year follow-up. Part 1: multivariate survival analysis. → *Clin Oral Implants Res.* 2015 Nov;26(11):1345–54.
18. Mengel R, Flores-de-Jacoby L. Implants in patients treated for generalized aggressive and chronic periodontitis: a 3-year prospective longitudinal study. → *J Periodontol.* 2005 Apr;76(4):534–43.
19. Rosenberg ES, Cho SC, Elian N, Jalbout ZN, Froum S, Evian CI. A comparison of characteristics of implant failure and survival in periodontally compromised and periodontally healthy patients: a clinical report. → *Int J Oral Maxillofac Implants.* 2004 Nov-Dec;19(6):873–9.
20. Pozzi A, Tallarico M, Moy PK. Three-year post-loading results of a randomised, controlled, split-mouth trial comparing implants with different prosthetic interfaces and design in partially posterior edentulous mandibles. → *Eur J Oral Implantol.* 2014 Spring;7(1):47–61.
21. Isidor F. Influence of forces on peri-implant bone. → *Clin Oral Implants Res.* 2006 Oct;17 Suppl 2:8–18.
22. Wennerberg A, Albrektsson T. On implant surfaces: a review of current knowledge and opinions. → *Int J Oral Maxillofac Implants.* 2010 Jan-Feb;25(1):63–74.
23. Östman PO, Hellman M, Sennerby L. Ten years later. Results from a prospective single-centre clinical study on 121 oxidized (TiUnite™) Brånemark implants in 46 patients. → *Clin Implant Dent Relat Res.* 2012 Dec;14(6):852–60.
24. Albouy JP, Abrahamsson I, Persson LG, Berglundh T. Spontaneous progression of peri-implantitis at different types of implants. An experimental study in dogs. I: clinical and radiographic observations. → *Clin Oral Implants Res.* 2008 Oct;19(10):997–1002.